



ASNC AND EANM CARDIAC AMYLOIDOSIS PRACTICE POINTS

^{99m}Techne^{tium}-
3,3-diphosphono-
1,2-propanodicarboxylic
acid (DPD) and ^{99m}Techne^{tium}
hydroxymethylene diphosphonate
(HMDP) Imaging for Transthyretin
Cardiac Amyloidosis

^{99m}Techneium-3,3-diphosphono-1,2-propanodicarboxylic acid (DPD) and ^{99m}Techneium-hydroxymethylene diphosphonate (HMDP) Imaging for Transthyretin Cardiac Amyloidosis

OVERVIEW

The purpose of this document is to identify the critical components involved in performing ^{99m}Techneium-3,3-diphosphono-1,2-propanodicarboxylic acid (^{99m}Tc-DPD) or ^{99m}Techneium-hydroxymethylene diphosphonate (^{99m}Tc-HMDP) imaging for the evaluation of cardiac transthyretin amyloidosis (ATTR).

BACKGROUND

- The majority of individuals with cardiac amyloidosis have myocardial amyloid deposits formed from misfolded light chain (AL) or transthyretin (TTR) proteins. Diagnosis of amyloidosis and differentiation between subtypes is important for prognosis, therapy, and genetic counseling.
- Cardiac ATTR amyloidosis, the focus of this practice points document, is an under-diagnosed cause of heart failure.
- Amyloid derived from wild-type TTR results in a restrictive cardiomyopathy, most commonly presenting in men who are in their late 60s or early 70s, but occasionally in patients in their early 60s or younger. Although almost 1 in 4 males over the age of 80 years have some TTR-derived amyloid deposits in the myocardium at autopsy, its clinical significance remains unknown. In general, clinical manifestation of heart failure occurs when enough amyloid has been deposited to cause significant left ventricular (LV) wall thickening.(1)
- Approximately 3% to 4% of U.S. African Americans have a common inherited mutation of the TTR gene (Val142Ile, previously known as Val122Ile). This mutation is common in people of western African descent and produces a restrictive cardiomyopathy in a minority, but may contribute to heart failure in a higher proportion.(1)
- Cardiac amyloidosis should be suspected in individuals with heart failure and thickened ventricles with grade 2 or greater diastolic dysfunction on echocardiography, as well as in patients with an “apical sparing” pattern on LV global longitudinal strain imaging or typical findings on cardiac magnetic resonance imaging (CMR; diffuse late gadolinium enhancement, extracellular volume (ECV) expansion, or characteristic T1 relaxation times).

- In the past, the diagnosis of cardiac amyloidosis required endomyocardial biopsy and typing of the amyloid fibrils. This practice has changed; it is now rarely used since a non-invasive diagnostic imaging method using ^{99m}Tc-labeled bone-seeking agents is an alternative. ^{99m}Tc-labeled bone-seeking agents, such as ^{99m}Tc-DPD, ^{99m}Tc-HMDP, or ^{99m}Tc-pyrophosphate (PYP)(2,3,4) have been shown in several studies to have high sensitivity and specificity for the diagnosis of cardiac ATTR amyloidosis.
- Recent studies highlight the value of DPD, HMDP, and PYP in diagnosing cardiac ATTR and differentiating it from AL amyloidosis.(4)
- While echocardiography and CMR can detect and diagnose cardiac amyloidosis, ^{99m}Tc-DPD, HMDP, or PYP imaging is the only non-invasive modality that identifies ATTR-type cardiac amyloidosis with high specificity, and thereby avoids unnecessary endomyocardial biopsies and efficiently guides patient management.(5)
- This document highlights the use of ^{99m}Tc-DPD and HMDP in cardiac amyloidosis imaging as these compounds are mainly used outside the United States, while ^{99m}Tc- PYP is used in the United States.

PATIENT SELECTION

Patients with a clinical suspicion of cardiac ATTR amyloidosis, including, but not exclusively and per multisocietal consensus recommendations(6):

- Patients aged >60 years, with heart failure, with preserved ejection fraction, and unexplained increase in LV wall thickness (>12 mm);
- Patients of west African ancestry, aged >60 years with otherwise unexplained heart failure or increased LV wall thickness (>12 mm);
- Patients, especially >60 years, with clinical features associated with amyloidosis, such as bilateral carpal tunnel syndrome, low-flow low-gradient aortic stenosis, unexplained sensory motor neuropathy, resistant atrial arrhythmias, second-degree atrioventricular (AV) block, and discordance between ECG voltage and LV wall thickness in the absence of usual risk factors;
- Echo or CMR features of cardiac amyloidosis in a clinical setting suggestive of ATTR;
- Patients with ATTR neuropathy; and
- Patients who have tested positive for a known TTR gene mutation.

OBTAINING THE RADIOTRACER

- ^{99m}Tc -DPD and HMDP are readily available as unit doses from commercial radiopharmaceutical distributors or as commercial kits for preparation.
- Kits are supplied in a vial containing the bisphosphonate, a stannous reducing agent, and other excipients in the form of a powder, ready for labelling. These kits are approved for bone and cardiac (for the detection of myocardial infarction) imaging. (See respective package inserts for details of reconstitution of ^{99m}Tc -DPD and HMDP.
- The total-body effective dose from 15 mCi (555 MBq) of ^{99m}Tc -DPD or HMDP is estimated at 3.3 mSv.
- Although there are no large studies directly comparing the agents, the principles in this document apply similarly to ^{99m}Tc -DPD, ^{99m}Tc -HMDP, and ^{99m}Tc -PYP imaging.

TEST PREPARATION

- No specific test preparation is required.

IMAGING PROCEDURE

- Commonly used imaging procedures for ^{99m}Tc -DPD or HMDP imaging are shown in **Table 1** with more details in ASNC/multisocietal consensus recommendations.(7) Individual centers can modify imaging procedures based on local camera capabilities and expertise.
- Whole-body planar and chest/cardiac SPECT images are obtained two to three hours after injection of ^{99m}Tc -DPD or HMDP using the parameters listed in **Table 1**.
- Planar imaging is useful for visual interpretation, especially when negative, and when positive for quantification of the degree of myocardial uptake (see **Image Interpretation** section) by visual comparison to rib uptake.
- SPECT imaging is necessary in all cases with positive planar scintigraphy to
 - Avoid overlap of bone uptake;
 - Distinguish blood-pool activity from myocardial activity (3);
 - Assess the regional distribution of myocardial ^{99m}Tc -DPD or HMDP uptake;
 - Identify ^{99m}Tc -DPD or HMDP uptake in the interventricular septum (commonly involved in amyloidosis); and
 - Quantify the degree of myocardial uptake by comparison to rib uptake.

- Whole-body planar imaging may be helpful to identify uptake of ^{99m}Tc-DPD or HMDP in the shoulder and hip girdles (a specific sign of systemic ATTR amyloidosis)(6) and to identify a low bone soft-tissue uptake in the extremities, which is a sign for systemic ATTR amyloidosis).
- The value of ^{99m}Tc-DPD or HMDP imaging with the newer “cardiac-dedicated” SPECT cameras needs further validation (due to the inability to accurately display bone and lung ^{99m}Tc-DPD or HMDP uptake with these systems; see **Image Interpretation** section).

Table 1. Imaging Parameters for Cardiac ^{99m}Tc-DPD/HMDP Imaging

Imaging procedures	Parameters
Patient Preparation	No specific preparation. No fasting required.
Scan	Rest scan
Activity of ^{99m} Tc-DPD or HMDP	10–20 mCi (370-740 MBq) intravenously
Time between injection and acquisition	Recommended: 2 or 3-hour SPECT and planar
Imaging parameters	
Field of view	Recommended: Cardiac or chest; Optional: Whole-body planar
Image type	Recommended: Chest Planar or Chest/Cardiac SPECT Required: Cardiac/Chest SPECT if planar is positive Optional: Whole-body planar imaging
Position	Supine
Energy window	140 keV, 15–20%
Collimators	Low energy, high resolution
Matrix	Planar: 256 by 256, at least 64 by 64 is required. SPECT: 128 by 128, at least 64 by 64 is required.
Pixel size	3.5–6.5 mm
Planar imaging specific parameters	
Number of views*	Chest: Anterior and Lateral Whole body: From head to toe
Detector configuration	90 degrees
Image duration	Count based: 750,000 counts or 20 cm per minute
Magnification	1.46

SPECT imaging specific parameters	
Angular range	Recommended: 180 degrees; Optional: 360 degrees
Detector configuration	Recommended 90 degrees; Optional 180 degrees
ECG gating	Off; Nongated imaging
Number of views/ detector	40
Time per view	30 seconds per view
Magnification	1.0

*Anterior and lateral views can be obtained at the same time using a 90-degree detector configuration; lateral planar views or SPECT imaging may help separate sternal from myocardial uptake.

IMAGE INTERPRETATION

- The anterior and lateral planar images, as well as the reconstructed SPECT images, are reviewed in standard cardiac imaging planes using commercial software.
- Myocardial ^{99m}Tc -DPD and HMDP uptake patterns are categorized as absent, focal, diffuse, or focal on diffuse.

Quantifying Myocardial ^{99m}Tc -DPD and HMDP Uptake

Semi-quantitative: visual comparison to bone (rib) uptake at 3 hours

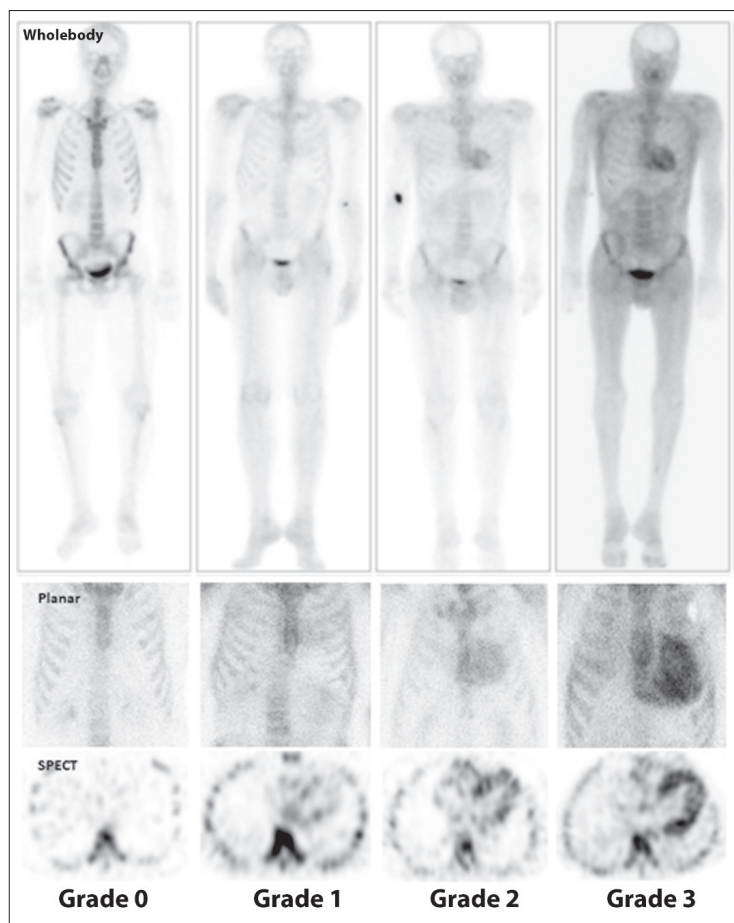
Cardiac uptake of ^{99m}Tc -DPD and HMDP is evaluated using a semi-quantitative visual scoring method in relation to bone (rib) uptake (**Table 2 and Figure 1**). Based on previously published results, visual scores of greater than or equal to 2 on planar (2, 3) or SPECT images at 3 hours (6) are classified as ATTR positive, and scores of less than 2 as ATTR negative.

While grade 2 or 3 is strongly suggestive of ATTR amyloidosis, any degree of ^{99m}Tc -DPD or HMDP myocardial uptake can occasionally be seen in AL amyloidosis. Therefore, DPD and HMDP should always be interpreted in conjunction with serum and urine immunofixation and serum free light chain assay studies to exclude AL amyloidosis.

Table 2. Semi-quantitative Visual Grading of Myocardial ^{99m}Tc -DPD/HMDP Uptake by Comparison to Bone (rib) Uptake

Grade	Myocardial ^{99m}Tc -DPD/HMDP Uptake
Grade 0	no uptake and normal rib uptake
Grade 1	uptake less than rib uptake
Grade 2	uptake equal to rib uptake
Grade 3	uptake greater than rib uptake with mild/absent rib uptake

Figure 1. Grading of Myocardial ^{99m}Tc -DPD/HMDP Uptake



Visual grading scale for cardiac uptake on whole-body (top) and chest (middle) planar imaging, and chest SPECT (bottom) imaging (from left to right: grade 0, 1, 2, and 3).

REPORTING

The report should include all elements of an ideal report as per standard ASNC/EANM guidelines.

Table 3. Myocardial ^{99m}Tc-DPD/HMDP Imaging Guideline for Reporting

Parameters	Elements
Demographics	Patient name, age, sex, reason for the test, date of study, prior imaging procedures, biopsy results if available (required)
Methods	Imaging technique, radiotracer dose and mode of administration, interval between injection and scan, scan technique (planar and SPECT) (required)
Findings	<ul style="list-style-type: none"> Image quality Visual scan interpretation (required) Semi-quantitative interpretation in relation to rib uptake (required)
Ancillary findings	<ul style="list-style-type: none"> Review whole-body planar images if acquired Interpret CT obtained for attenuation correction for unexpected findings (e.g., lung lesions) if SPECT/CT scanners are used
Conclusions	<ol style="list-style-type: none"> An overall interpretation of the findings into categories for ATTR cardiac amyloidosis, include: <ol style="list-style-type: none"> Not suggestive of ATTR amyloidosis; Strongly suggestive of ATTR amyloidosis; or Equivocal <ol style="list-style-type: none"> Not suggestive: A semi-quantitative visual score of 0 Strongly suggestive: A semi-quantitative visual score of 2 or 3 Equivocal: A semi-quantitative visual score of 1; Interpret the results in the context of prior evaluation <ol style="list-style-type: none"> If echo/CMR are strongly positive, and ^{99m}Tc-DPD/HMDP negative, consider further evaluation including endomyocardial biopsy The writing group would like to emphasize the importance of excluding a monoclonal process, with serum and urine immunofixation, and a serum free light chain assay, in all patients with suspected amyloidosis referred for ^{99m}Tc-DPD/HMDP scan irrespective of the scan results. Of note: equivocal or even positive results could represent AL amyloid or early ATTR cardiac amyloid.

REFERENCES:

- (1) Ruberg FL, Berk JL. Transthyretin (TTR) cardiac amyloidosis. *Circulation* 2012;126:1286-300.
- (2) Perugini E, Guidalotti PL, Salvi F, Cooke RM, Pettinato C, Riva L, et al. Noninvasive etiologic diagnosis of cardiac amyloidosis using ^{99m}Tc-3,3-diphosphono-1,2-propanodicarboxylic acid scintigraphy. *J Am Coll Cardiol* 2005;46:1076-84.
- (3) Treglia G, Glaudemans AWJM, Bertagna F, Hazenberg BPC, Erba PA, Giubbini R, et al. Diagnostic accuracy of bone scintigraphy in the assessment of cardiac transthyretin-related amyloidosis: a bivariate meta-analysis. *Eur J Nucl Med Mol Imaging* 2018;45(11):1945-1955.
- (4) Gillmore JD, Maurer MS, Falk RH, Merlini G, Damy T, Dispenzieri A, et al. Nonbiopsy Diagnosis of Cardiac Transthyretin Amyloidosis. *Circulation*. 2016;133:2404-12.
- (5) Hutt DF, Quigley AM, Page J, Hall ML, Burniston M, Gopaul D, et al. Utility and limitations of 3,3-diphosphono-1,2-propanodicarboxylic acid scintigraphy in systemic amyloidosis. *Eur Heart J Cardiovasc Imaging* 2014;15:1289-98.
- (6) Dorbala S, Ando Y, Bokhari S, Dispenzieri A, Falk RH, Ferrari VA, et al. ASNC/AHA/ASE/EANM/HFSA/ISA/SCMR/SNMMI Expert consensus recommendations for multimodality imaging in cardiac amyloidosis: Part 2 of 2—Diagnostic criteria and appropriate utilization. *J Nucl Cardiol* 2019. doi: 10.1007/s12350-019-01761-5.
- (7) Dorbala S, Ando Y, Bokhari S, Dispenzieri A, Falk RH, Ferrari VA, et al. ASNC/AHA/ASE/EANM/HFSA/ISA/SCMR/SNMMI Expert consensus recommendations for multimodality imaging in cardiac amyloidosis: Part 1 of 2—Evidence base and standardized methods of imaging. *J Nucl Cardiol* 2019. doi: 10.1007/s12350-019-01760-6.

ASNC thanks the following members for their contributions to this document:

Writing Group:

Sharmila Dorbala, MD, MPH (Chair)
Sabahat Bokhari, MD
Andor W.J.M. Glaudemans, MD, PhD
Edward Miller, MD, PhD
Renee Bullock-Palmer, MD
Riemer H.J.A. Slart, MD, PhD
Prem Soman, MD, PhD
Randall Thompson, MD
Hein J. Verberne, MD, PhD

Reviewers:

Wael AlJaroudi, MD
Andrew Einstein, MD, PhD
Olivier Gheysens, MD, PhD
Fabien Hyafil, MD, PhD

Version History:

First Issued: September 2019

Adapted from ASNC 99mTechnetium-Pyrophosphate Imaging for Transthyretin Cardiac Amyloidosis Practice Points February 2019

Copyright © 2019 American Society of Nuclear Cardiology



American Society of Nuclear Cardiology

www.asnc.org

